

Case Report:

Anwendung des Fasciotens[®] Abdomen Systems bei verzögertem primären Faszienverschluss und dabei beobachtete physiologische Verbesserung des Patienten*

Mavc Z., Kunst G.

Stabilisierende Effekte:

- Reduktion des FiO_2 : von 60% auf 30%
- Reduktion des positiven endexpiratorischen Drucks: von 14cm H_2O auf 9cm H_2O
- Steigerung der Diurese: von 100ml/h auf 300ml/h

Physiologische Rationale:

- Verbesserung der kardialen Vorlast
- Erhöhung der Lungencompliance
- Zunahme des intraabdominellen Volumens bei reduziertem intraabdominellen Druck

November 2023

Case report

Case report: Fasciotens© Abdomen system application for delayed primary fascial closure and observed physiological improvement of the patient

Mavc Z¹, Kunst G¹

1 Department of General and Abdominal Surgery, Slovenj Gradec General Hospital

Keywords: Fasciotens, open abdomen treatment, delayed primary fascial closure

Correspondence

Gregor Kunst,
gregor.kunst@sb-sg.si

Article info

Surgery Surg Endos
2023; 5(1) Suppl. 2: 62-
67

Abstract

Open abdomen therapy is often necessary for patients with abdominal compartment syndrome, septic peritonitis, or abdominal trauma. In cases with prolonged open abdomen therapy, fascial retraction often prevents primary fascial closure despite the use of established techniques for temporary abdominal closure. We present a case in which we attempted primary fascial closure with the application of a Fasciotens© Abdomen device after prolonged open abdomen therapy. In addition to the successful primary fascial closure of the abdominal wall, we observed some physiological improvements in the patient that contributed to his positive outcome.

INTRODUCTION

Management of patients with abdominal compartment syndrome, septic peritonitis, or abdominal trauma often requires open abdomen (OA) therapy [1]. Although OA therapy is essential for the survival of the patient in these settings, it raises the risk of other complications associated with this approach, such as multiple organ failure, enterocutaneous fistula formation, and intraabdominal abscess formation [1]. Early closure of the abdominal wall is prioritized to avoid these complications. Many techniques are described for

temporary abdominal closure during OA therapy. These include negative pressure wound therapy, Bogota bag, skin closure only, and fascial traction devices [2]. One of the main purposes of these techniques is the prevention of fascial retraction so primary fascial closure can be achieved. According to Granger et al., the probability of primary myofascial closure in case of negative pressure wound therapy using the ABThera™ system declines down to 0% on the sixth day after laparostomy. In contrast to the previously described methods, Fasciotens archives not only prevention of fascial retraction but can also be applied for fascial length gain.

November 2023

In this case, report, we represent you, a patient who underwent urgent surgery for generalized peritonitis caused by small bowel perforation. For twenty-five days, he was mainly treated with an appliance of the ABThera system. After regression of generalized peritonitis, Fasciotens© Abdomen was applied for six days in combination with the ABThera™ system. At this time, the fascial defect of the median laparotomy was reduced down from 15 cm to 0-1 cm, so tension-free primary fascial closure of the abdomen was achieved. Immediately after the application of the Fasciotens© Abdomen system, improvement of respiratory dynamics, higher diuresis, increased stoma output, and improvement of hemodynamics were observed.

CASE PRESENTATION

A 43-year-old morbidly obese patient with a BMI of 53.9 was admitted to our department in May 2023 for two days, lasting upper abdominal pain that began after lifting a heavy object. The pain was later accompanied by vomiting and reduced bowel movement with no record of fever. Previously, the patient had been treated four times for a ventral hernia. He described the course of the latest episode of epigastric pain as similar to the one experienced during the last incarcerated hernia.

During the examination, numerous scars from previous surgical interventions were found on the abdomen. An induration was found in the upper part of the abdomen, measuring 8x8 cm in size, with relatively well-defined margins and significant tenderness.

An abdominal X-ray revealed dilatation of the small intestinal loops up to 35 mm and multiple air-fluid levels. An ultrasound (US) showed a ventral hernia with incarcerated small intestine loops located craniolateral to the umbilicus, with a dilatation of up to 5 cm.

The patient underwent emergency surgery. Preoperatively, he received gentamicin and metronidazole. During the operation, a perforation of the distal ileum was discovered as a result of incarceration. Multiple herniated defects with trapped omentum were found on the anterior abdominal wall. Small bowel resection and enter-enter anastomosis were performed. Due to generalized peritonitis, the ABThera™ system was applied. After the surgery, the patient was admitted to the surgical intensive care unit.

On the second postoperative day, a double-look procedure revealed a dehiscence of anastomosis. The affected part of the small intestine was resected together with the ascending colon. The transverse colon was blindly closed, and a terminal ileostomy was performed. The ABThera™ system was applied again and then changed every two days.

On the fifteenth postoperative day, we decided to close the abdomen since there was no sign of active peritonitis. Due to substantial fascial retraction, the abdomen was completed only with approximation of the skin and subcutaneous tissue.

A rise in inflammatory parameters was observed on the eighteenth postoperative day. A control CT scan showed a fluid collection near the transverse colon stump (Figure 1).

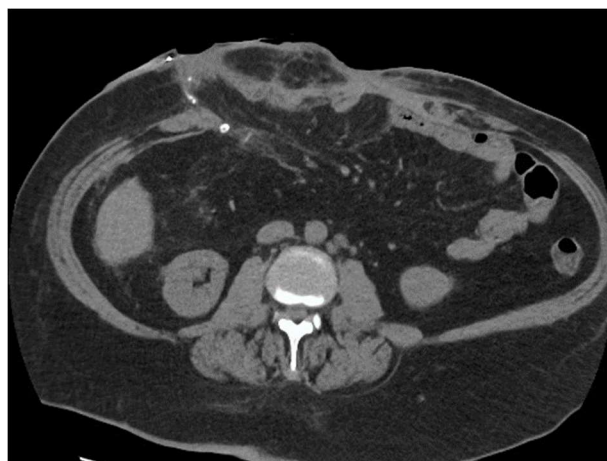

Figure 1: CT scan showing a large ventral hernia

November 2023

Relaparotomy was performed, which showed no signs of dehiscence. Due to higher inflammatory parameters, lavage was completed, and the ABThera™ system was reinstalled. The plan was changed every two to three days.

On the twenty-fifth postoperative day, with low inflammatory parameters values and no signs of peritonitis, we decided to install the Fasciotens© Abdomen system in combination with the ABThera™ system for primary closure of the abdominal wall fascia (Figure 2).

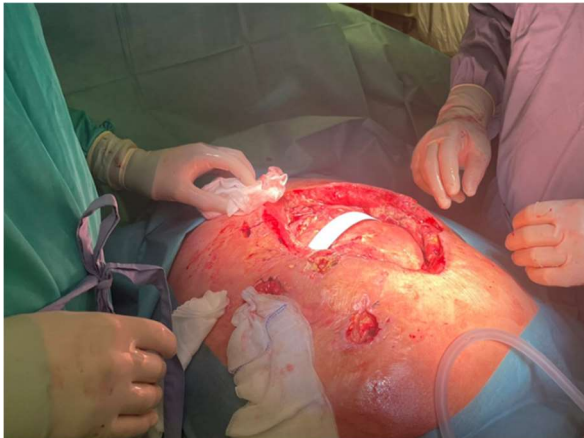


Figure 2: Fascial gap of 15 cm before Fasciotens© Abdomen installation

Installation was placed according to instructions and under direct supervision by the leading surgeon at Fasciotens (Figure 3). Immediately after the patient's readmission to the ICU, improvements in vital parameters were seen. Within one hour, the need for additional oxygen was reduced from 60% to 30 %, positive end-expiratory pressure was reduced from 14 cmH₂O to 9 cmH₂O, and diuresis increased from 100 mL/h up to 300 mL/h. Over 24 hours, indirect signs of improved peristalsis were also seen. Stoma output increased from 100mL/8h up to 850mL/8h, and nasogastric tube output decreased from 300 mL/h down to 50 mL/h. There were no changes in medicamentous therapy before these physiological changes, although the patient was treated with diuretics and prokinetics. With the Fasciotens© Abdomen system applied, the

dosage of diuretics was decreased the following day.

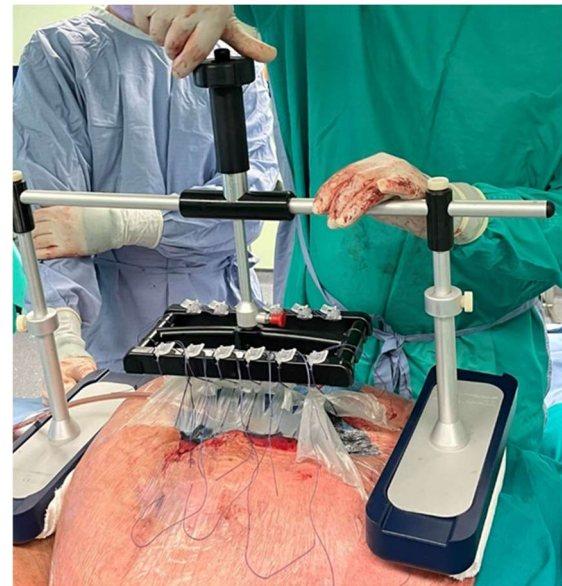

Figure 3: Installation of Fasciotens© Abdomen

On the twenty-eighth postoperative day (three days after applying Fasciotens), the wound dressing was changed. During the procedure, we placed a few individual fascia sutures at both ends of the median laparotomy since there was no fascial gap in these areas. On the thirty-first day (six days after the application of Fasciotens), when reviewing the wound, we observed the gap between the two edges of the anterior abdominal fascia had reduced to the point where primary closure was possible. We removed the Fasciotens© Abdomen system and closed the fascia with individual sutures, followed by the placement of situational sutures of the skin and subcutaneous tissue. The patient was under general anesthesia the whole time of treatment with the Fasciotens© Abdomen system. During the installation of the system and closure of the fascia, total relaxation was achieved.

The patient was then treated in the ICU for another 39 days after the last surgical intervention. He was then transferred to our Department of General and Abdominal Surgery, where intensive physiotherapy was continued. Before discharge from the hospital, a control CT scan of the abdomen was performed

November 2023

(Figure 4). No sign of dehiscence along median laparotomy was observed, although multiple fascial defects of the anterior abdominal wall were still seen. He continued with his rehabilitation and physical therapy in the medical center.

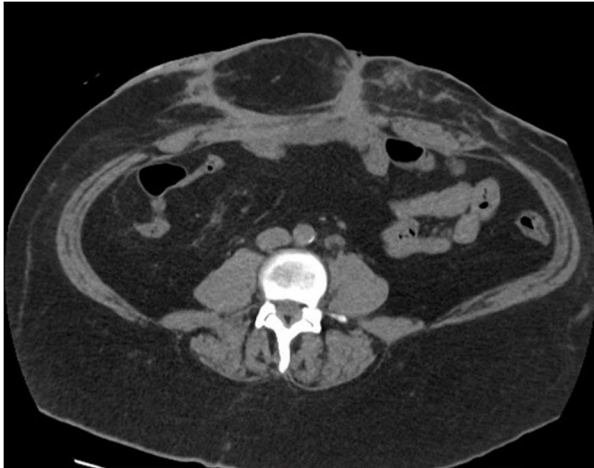


Figure 4: CT scan before discharge. No dehiscence along median laparotomy.

DISCUSSION

In our case, the patient underwent prolonged open abdomen (OA) therapy due to generalized peritonitis. After the first fifteen days of OA therapy, the core was closed only with an approximation of the skin and subcutaneous tissue. Primary fascial closure was not possible due to substantial fascial retraction, despite continuous therapy with the ABThera™ system, which correlates with the conclusions of Granger et al. since primary fascial closure was attempted much later than within six days of laparotomy [2].

In the represented case, a novel device that prevents fascial retraction and facilitates early abdominal wall closure was implemented on the twenty-fifth postoperative day. We decided to apply the device in avoidance of early postoperative hernia along the midline laparotomy, mainly because there were multiple other fascial defects. In combination with this device, the ABThera™ system was applied. During both wound dressing changes, we observed a significant reduction in the gap between both

fascial margins. Delayed primary fascial closure was achieved within two separate procedures. Despite OA for a little over three weeks before Fasciotens© Abdomen application, closure of the patient's septic abdomen was completed six days after the continuous appliance of dynamic tension on the fascia [1]. Fung et al. describe primary fascial closure in their first reported case of Fasciotens© Abdomen only after two weeks of therapy. The shorter timeframe of primary fascial closure in our case could be explained by multiple fascial defects, which may have served similarly to fascial release incisions.

Within hours after the installation of Fasciotens© Abdomen, changes in physiological parameters were observed, although no difference in medicamentous therapy was made. Respiratory parameters and signs of improved peristalsis were some of the most apparent changes. Upon review of the literature, this could be explained by decreased blood pooling in splanchnic vasculature after installation of the device [3]. In critically ill patients, fluid overload may lead to several complications, like pulmonary edema, delayed wound healing, tissue breakdown, and impaired bowel function [4]. In our case, higher urine output after installation of the device indicated an improved perfusion of the kidneys. Higher stoma output and reduced nasogastric output could show improvement in peristalsis due to changes in the microcirculation of the small intestine or, in other words, regression of intestinal edema. In just three days, with Fasciotens© Abdomen installed, approximately 8 liters of excessive fluid was excreted from the patient's body.

CONCLUSION

The implementation of Fasciotens© Abdomen, in our case, prevented further fascia retraction and achieved some fascial length gain. It enabled successful fascial closure and, by that, stopped or at least postponed complications in terms of postoperative hernia along median laparotomy. It

November 2023

is essential that we were able to return all layers of the anterior abdominal wall to the anatomical position since there were multiple defects in the fascia. This reduces the extensiveness of the procedure in case of delayed hernioplasty of these defects. Besides conditioning primary fascial closure, the appliance of the device brought some unexpected benefits in terms of physiological improvements. Since this is the only reported case with such findings so far, a prospective study with a more significant number of patients is needed to investigate the reliability of our results.

STATEMENTS AND DECLARATIONS

Competing Interests: Not applicable.

Funding: Not applicable.

Acknowledgments: Not applicable.

Informed Consent Statement: Informed consent was obtained from all subjects involved in the study. Written informed consent has been obtained from the patient(s) to publish this paper.

Ethics approval: The study was approved by the local ethnics committee.

Conflicts of Interest: None declared.

Consent for publication: Not applicable.

REFERENCES

1. Fung, Stephen. "Fasciotens© Abdomen ICU: Novel Device Prevents Abdominal Wall Retraction and Facilitates Early Abdominal Wall Closure of Septic Open Abdomen." (2019).
2. Granger S, Fallon J, Hopkins J, Pullyblank A. An open and closed case: timing of closure following laparostomy. *Ann R Coll Surg Engl.* 2020 Sep;102(7):519-524. doi: 10.1308/rcsann.2020.0105. Epub 2020 Jun 15. PMID: 32538103; PMCID: PMC7450447.
3. Aliverti A, Bovio D, Fullin I, Dellacà RL, Lo Mauro A, Pedotti A, Macklem PT. The abdominal circulatory pump. *PLoS One.* 2009;4(5):e5550. doi: 10.1371/journal.pone.0005550. Epub 2009 May 14. PMID: 19440240; PMCID: PMC2678249.
4. Claire-Del Granado, R., Mehta, R.L. Fluid overload in the ICU: evaluation and management. *BMC Nephrol* 17, 109 (2016). <https://doi.org/10.1186/s12882-016-0323-6>
5. Weinberg JA, George RL, Griffin RL, Stewart AH, Reiff DA, Kerby JD, Melton SM, Rue LW 3rd. Closing the open abdomen: improved success with Wittmann Patch staged abdominal closure. *J Trauma.* 2008 Aug;65(2):345-8. Doi: 10.1097/TA.0b013e31817fa489. PMID: 18695469.
6. Hees A, Willeke F. Prevention of Fascial Retraction in the Open Abdomen with a Novel Device. *Case Rep Surg.* 2020 Oct 21;2020:8254804. Doi: 10.1155/2020/8254804. PMID: 33145116; PMCID: PMC7599407.
7. Fung S, Ashmawy H, Krieglstein C, Halama T, Schilawa D, Fuckert O, Hees A, Kröpil F, Rehders A, Lehwald-Tywuschik NC, Knoefel WT. Vertical traction prevents abdominal wall retraction and facilitates early primary fascial closure of septic and non-septic open abdomen. *Langenbecks Arch Surg.* 2022 Aug;407(5):2075-2083. doi: 10.1007/s00423-021-02424-1. Epub 2022 Feb 11. PMID: 35147749; PMCID: PMC8832079.
8. Travis TE, Prindeze NJ, Shupp JW, Sava JA. Intra-abdominal Pressure Monitoring During Negative Pressure Wound Therapy in the Open Abdomen. *J Surg Res.* 2022 Oct;278:100-110. doi: 10.1016/j.jss.2022.04.019. Epub 2022 May 18. PMID: 35597024.
9. Aguilar-Frasco J, Moctezuma-Velázquez P, Rodríguez-Quintero JH, Pastor-Sifuentes FU, Garcia-Ramos ES, Clemente-Gutierrez U, Morales-Maza J, Santes O, Hernández-Acevedo JD, Contreras-Jimenez E, Y Terán SM. Myths and

November 2023

realities in managing the open abdomen with negative pressure systems. A case report and literature review. *Int J Surg Case Rep.* 2019;61:174-179. doi: 10.1016/j.ijscr.2019.07.047. Epub 2019 Jul 22. PMID: 31376738; PMCID: PMC6677784.